

**PATIENT**

Maddi Hull  
50873A

**SPECIES**

Canine

**BREED**

Cockapoo

**SEX**

Spayed Female

**AGE**

14 years, 3 mos

**WEIGHT**

8.2 kg

**INTERPRETED BY**

Andrea Nicastro,  
DVM, Diplomate  
ACVIM (Small Animal  
Internal Medicine)

**IMAGING  
PERFORMED BY**

Tom McNeill

**HOSPITAL NAME**

SVS Imaging CT

**REFERRING VET**

Madison Vet Spec Dr.  
Patton

**INVOICE**

11536

**DATE**

8.31.22

**PRESENTING CLINICAL SIGNS**

History: Patient presented today for a cholecystectomy. Was given Cerenia as a pre-operative medication and shortly collapsed thereafter. Blood sugar was 58 after collapse. Patient is hypotensive. Previously seen in May 2022 for lethargy, vomiting, inappetence, and abdominal pain. Ultrasound was performed and patient was diagnosed with mild acute pancreatitis and suspect partial or incomplete gallbladder mucocele.

**ULTRASONOGRAPHIC EXAMINATION OF THE ABDOMEN**

**Urinary System**

The **urinary bladder** is contracted. The wall is of appropriate thickness for the level or repletion. No cystic calculi are observed.

The **left kidney** is normal size (3.91 cm in length); normal shape and architecture with smooth peripheral margins. There is a normal 1:3 cortex to medulla ratio with minimal to mild loss of corticomedullary distinction. There is no evidence of pyelectasia, nephroliths, infarcts or hydroureter. Renal vasculature is normal.

The **right kidney** is normal size (3.99 cm in length); normal shape and architecture with smooth peripheral margins. There is a normal 1:3 cortex to medulla ratio with minimal to mild loss of corticomedullary distinction. There is no evidence of pyelectasia, nephroliths, infarcts or hydroureter. Renal vasculature is normal.

**Adrenal Glands**

The **left adrenal gland** is normal size (0.46 cm at cranial pole) (0.52 cm at caudal pole) (2.15 cm in length); normal shape; homogenous parenchyma. The glandular echogenicity and detail are unremarkable. Capsule, cortex, and medullary definition are normal. The phrenicoabdominal vein and surrounding vasculature are normal.

The **right adrenal gland** is normal size (0.65 cm at cranial pole) (0.37 cm at caudal pole); normal shape; homogenous parenchyma. The glandular echogenicity and detail are unremarkable. Capsule, cortex, and medullary definition are normal. The phrenicoabdominal vein and surrounding vasculature are normal.

**Spleen**

The **spleen** is subjectively normal in size (0.97 cm in width at the level of the hilus) with normal curvilinear peripheral contours. The parenchyma is subtly mottled in appearance. A 0.47 cm hypoechoic nodule is observed at the cranial aspect. Splenic vasculature appears normal with no evidence of thrombosis.

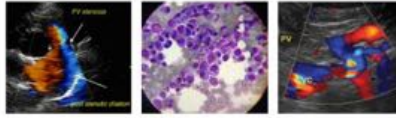
**Liver**

The **liver** is normal to slightly prominent in size with normal curvilinear peripheral contours. The parenchyma is isoechoic relative to the spleen and exhibits mild heterogeneity. A few, small, ill-defined hypoechoic nodules/areas are observed. Hepatic vasculature and biliary tracts are of normal volume with no evidence of congestion.

The **gall bladder** lumen is moderately distended. The wall is thin and smooth. A small amount of aggregated, echogenic debris is observed within the lumen, some of which is partially dependent, and some of which is suspended. The cystic and common bile ducts are normal/not seen.

**Gastrointestinal**

The **stomach and intestine** are free of stasis and exhibit normal peristaltic activity. The gastric lumen is not distended. The gastric wall and pylorus are normal in thickness with a normal layering pattern. The pyloric outflow tract is patent. The small intestinal lumen is not dilated. The small intestinal wall thickness is normal with a normal layering pattern and appropriate mural



**PATIENT**

Maddi Hull  
50873A

**SPECIES**

Canine

**BREED**

Cockapoo

**SEX**

Spayed Female

**AGE**

14 years, 3 mos

**WEIGHT**

8.2 kg

**INTERPRETED BY**

Andrea Nicastro,  
DVM, Diplomate  
ACVIM (Small Animal  
Internal Medicine)

**IMAGING  
PERFORMED BY**

Tom McNeill

**HOSPITAL NAME**

SVS Imaging CT

**REFERRING VET**

Madison Vet Spec Dr.  
Patton

**INVOICE**

11536

**DATE**

8.31.22

detail. Discreet masses are not identified. The colonic wall is normal. There is no evidence of an obstructive pattern.

**Pancreas**

The right limb of the **pancreas** is normal in size with normal curvilinear peripheral contours. The parenchyma is largely isoechoic relative to surrounding omental fat and slightly mottled in appearance. The pancreatic duct is visible but not overtly dilated. There is no evidence of peripancreatic inflammation or effusion.

**Free Abdomen**

The **peritoneal cavity** is normal. There is no evidence of inflammation or effusion. The abdominal **lymph nodes** are normal/not visible.

**Other**

The caudal vena cava is subjectively contracted relative to the aorta.

**ULTRASONOGRAPHIC FINDINGS**

**Primary Findings**

- Gall bladder debris, non-mucocele
- The diffuse hepatic changes are non-specific and could be consistent with vacuolar hepatopathy, regenerative nodular hyperplasia, and/or age-related remodeling. Inflammatory and infiltrative disease are considered less likely. However, correlation with the patient's liver values is recommended.

**Secondary Findings**

- The splenic parenchymal changes are most consistent with a benign process such as lymphoid hyperplasia, extramedullary hematopoiesis, splenitis or antigenic stimulation with a low possibility of infiltrative neoplasia (i.e., lymphoma, mast cell neoplasia).
- Minor, bilateral degenerative renal changes
- Mild age-related pancreatic remodeling
- The contracted caudal vena cava is consistent with the patient's history of hypotension.

\*An obvious cause for the patient's hypoglycemia is not identified in this study.

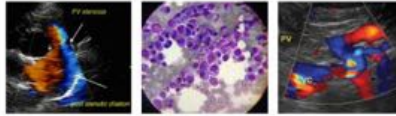
Considerations include insulinoma, hepatic dysfunction, hypoadrenocorticism (less likely), sepsis (less likely) paraneoplastic syndrome, other.

**INTERPRETATION OF THE FINDINGS & FURTHER RECOMMENDATIONS**

Baseline lab work, including a CBC, Chemistry panel, urinalysis and T4, is recommended, if not already performed.

Regarding the hypoglycemia, consider the following:

1. Insulin: glucose ratio
2. Pre-and postprandial serum bile acids to assess hepatic function
3. A resting cortisol level to screen for hypoadrenocorticism
4. Three-view thoracic radiographs to evaluate for occult disease/neoplasia in the chest
5. While awaiting test results, supportive care for shock/hypotension is recommended.



**PATIENT**

Based on the sonograph changes of the gall bladder, a cholecystectomy is not indicated at this time. However, serial sonographic monitoring (i.e, every 6-8 weeks) should be considered to assess for the development of organized sludge.

Maddi Hull  
50873A

**SPECIES**

Canine

**BREED**

Cockapoo

**SEX**

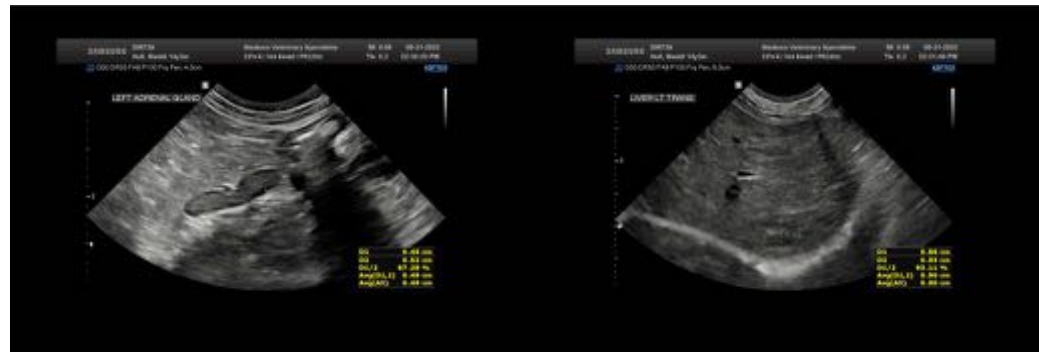
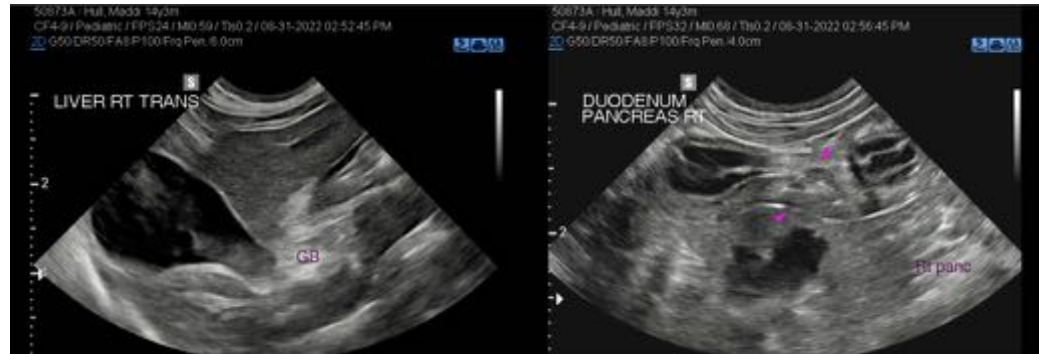
Spayed Female

**AGE**

14 years, 3 mos

**WEIGHT**

8.2 kg

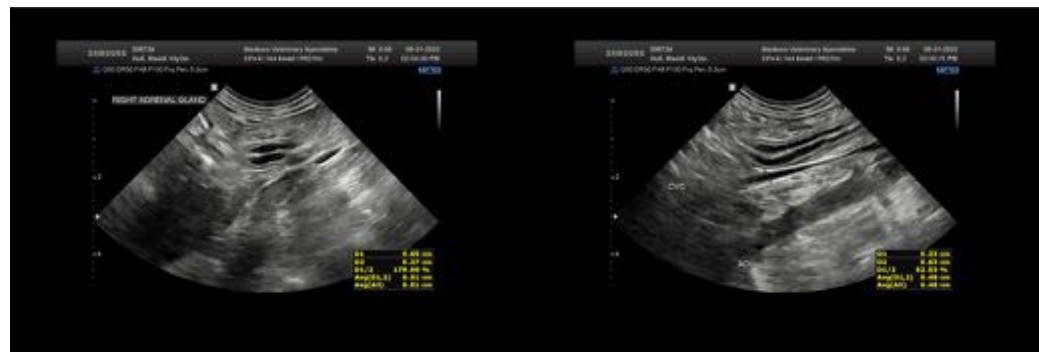

**INTERPRETED BY**

Andrea Nicastro,  
DVM, Diplomate  
ACVIM (Small Animal  
Internal Medicine)

**IMAGING  
PERFORMED BY**

Tom McNeill



**HOSPITAL NAME**

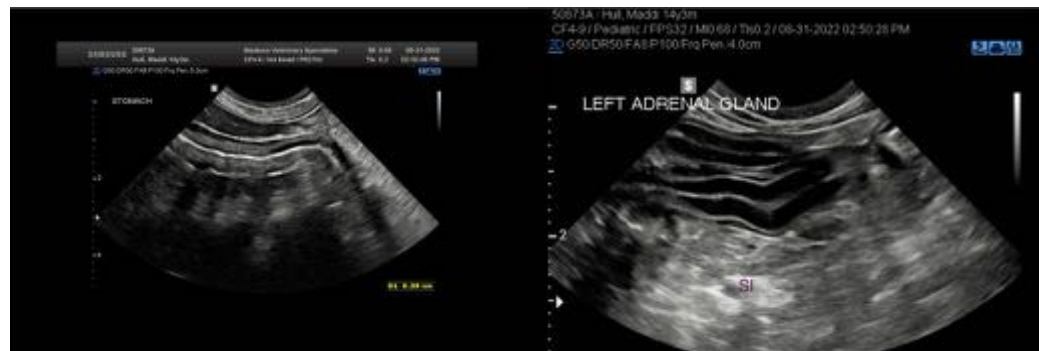SVS Imaging CT

**REFERRING VET**

Madison Vet Spec Dr.  
Patton

**INVOICE**

11536



**DATE**

8.31.22

IMAGING PERFORMED BY

svsimagingqc.net 309-737-3070



Clinical Sonography & Telectology

EDUCATIONAL TELECONSULTATION SERVICES™

1-800-838-4268 info@sonopath.com SonoPath.com

**PATIENT**

Maddi Hull  
50873A

**SPECIES**

Canine

**BREED**

Cockapoo

**SEX**

Spayed Female

**AGE**

14 years, 3 mos

**WEIGHT**

8.2 kg

**INTERPRETED BY**

Andrea Nicastro,  
DVM, Diplomate  
ACVIM (Small Animal  
Internal Medicine)

**IMAGING  
PERFORMED BY**

Tom McNeill

**HOSPITAL NAME**

SVS Imaging CT

**REFERRING VET**

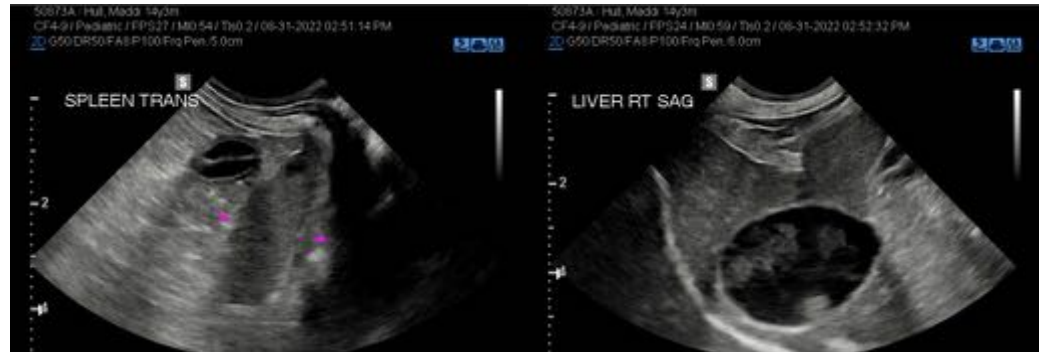
Madison Vet Spec Dr.  
Patton

**INVOICE**

11536

**DATE**

8.31.22



The information and recommendations provided are based on the images presented by the referring veterinarian/sonographer. No evaluation can be communicated regarding pathology that was not visible in the image/video clips provided.

Thank you for this referral. If the clinical or image interpretation does not parallel your findings or if I can be of any further assistance, please contact me.

**Andrea Nicastro, MPH, DVM, Diplomate DACVIM (Small Animal Internal Medicine)**  
[info@SonoPath.com](mailto:info@SonoPath.com)